

Primary Membranous Nephropathy Flare After COVID-19 Vaccination

Kelly V. Liang^{1,*}, Syeda B. Ahmad², Elizabeth C. Kurtz², Matthew Pittappilly²,
Marta I. Minervini³

¹Department of Medicine, Division of Nephrology and Hypertension, Jared Grantham Kidney Institute, University of Kansas Medical Center, USA

²Department of Medicine, Renal-Electrolyte Division, University of Pittsburgh Medical Center, USA

³Department of Pathology, University of Pittsburgh Medical Center, USA

Case Report
Open Access &
Peer-Reviewed Article

DOI: 10.14302/issn.2574-4488.jna-24-5219

Running title:

Membranous nephropathy flare after COVID-19 vaccination

Corresponding author:

Kelly V. Liang, Department of Medicine, Division of Nephrology and Hypertension, Jared Grantham Kidney Institute, University of Kansas Medical Center, USA

Keywords:

Membranous nephropathy, COVID-19, vaccines, flares, glomerular diseases, PLA2R

Received: July 31, 2024

Accepted: August 28, 2024

Published: September 05, 2024

Citation:

Kelly V. Liang, Syeda B. Ahmad, Elizabeth C. Kurtz, Matthew Pittappilly, Marta I. Minervini (2024) Primary Membranous Nephropathy Flare After COVID-19 Vaccination. *Journal of Nephrology Advances* - 1(4):12-18. <https://doi.org/10.14302/issn.2574-4488.jna-24-5219>

Abstract

Primary membranous nephropathy (MN) is due to autoantibodies to phospholipase A2 receptor (PLA2R Ab). It is unclear whether COVID-19 vaccines can trigger flares of glomerular diseases such as primary MN. There have been increasing reports of glomerular diseases presenting or flaring after receipt of COVID-19 vaccines. We present a patient with primary MN who developed nephrotic syndrome after receiving her second mRNA-1273 COVID-19 vaccine with positive PLA2R Ab. Renal biopsy confirmed primary MN. She was treated for her primary MN flare with rituximab in a manner similar to non-vaccine-associated MN, which led to significant reduction in both PLA2R Ab level and proteinuria. This case adds to the growing literature on MN flares after receipt of mRNA COVID-19 vaccines. Close follow-up of patients with primary MN and other glomerular diseases after COVID-19 vaccination is warranted. Further research is needed to determine the pathophysiology behind vaccine-induced MN flares and whether there is a potential association between exposure to SARS-CoV-2 antigens and loss of tolerance to the PLA2R antigen.

Introduction

Primary membranous nephropathy (MN) is most commonly due to phospholipase A2 receptor antibodies (PLA2R Ab). It is unclear whether the COVID-19 vaccine can trigger flares of glomerular diseases such as primary MN. Recently, there have been increasing reports of MN either presenting de novo or flaring after receipt of a COVID-19 vaccine. We present a patient with MN and metastatic breast cancer who developed nephrotic syndrome after receiving her second mRNA-1273 COVID-19 vaccine with positive PLA2R Ab suggesting primary MN flare. The objectives of this case report include: 1) To raise awareness of the risk for relapse of primary MN after mRNA COVID-19 vaccination; and 2) To review the literature on the association between COVID-19 vaccines and glomerular disorders.

Case Presentation

A 62 year old female with history of Stage IIIB T3N3M0 ER/PR positive HER-2 negative left breast invasive ductal carcinoma, hypertension, hyperlipidemia, and primary MN presented with bilateral leg edema, dyspnea, and proteinuria 2 weeks after COVID-19 vaccination. She had a history of nephrotic syndrome due to primary MN. 24h urine total protein in August 2018 was 7029 mg/24h and PLA2R Ab was 128 RU/mL (negative <14, borderline 14-19, positive >19) in Oct 2018. She was diagnosed with left breast ductal carcinoma and underwent modified radical mastectomy in September 2018 followed by adjuvant chemotherapy (Adriamycin and Cyclophosphamide x 4 cycles followed by Taxol x 12 cycles) from November 2018 to April 2019. In February 2019, her PLA2R Ab decreased to <2 RU/mL. In April 2019, her urine protein/Cr ratio (UPCR) decreased to 1094 mg/g Cr. She was treated with furosemide, metolazone, and lisinopril. In April 2019, imaging discovered retroperitoneal & left common iliac lymphadenopathy, pulmonary nodules, and prominent left adrenal gland (also seen in 2018), suggestive of metastatic breast carcinoma. She refused chest wall and lymph node radiation and was started on adjuvant anastrozole. She stopped taking lisinopril and furosemide in 2019.

She received mRNA-1273 COVID-19 vaccines in late January and February 2021. In March 2021, two weeks after her second vaccine dose, she presented with bilateral leg edema, dyspnea, and bilateral

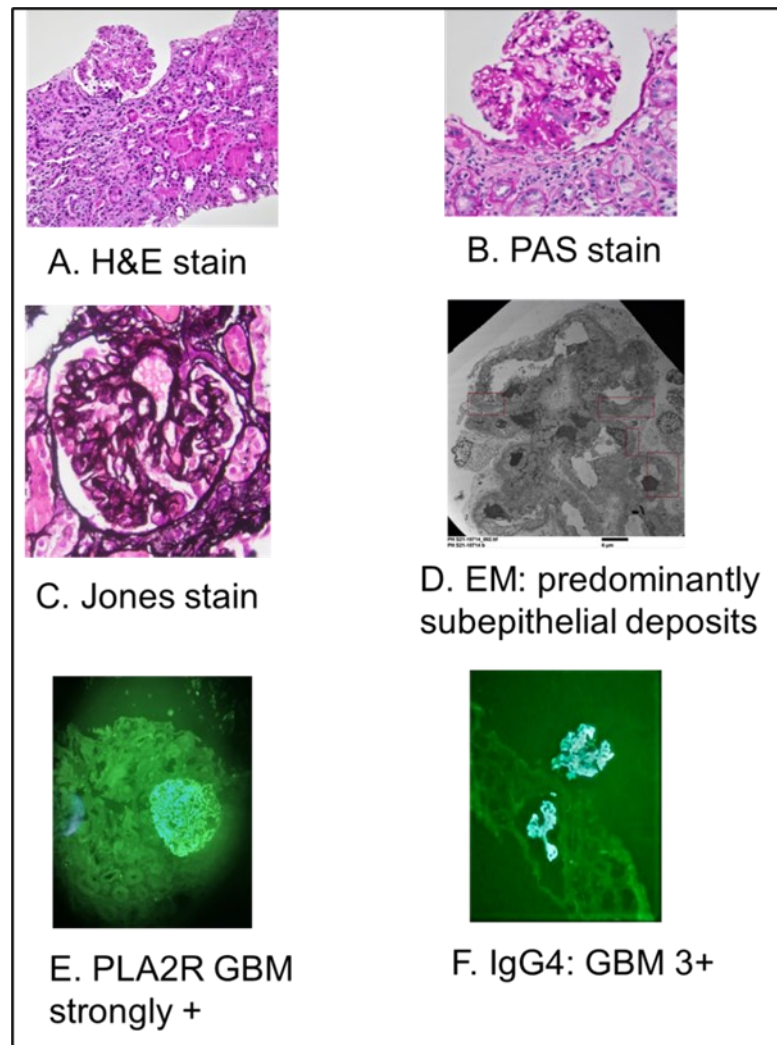


Figure 1. Renal biopsy pathology

Table 1. Clinical laboratory parameters over time

Date	24-h Urine protein (mg/24h) or UPCR (mg/g Cr)	PLA2R Ab (RU/mL) (negative <14, borderline 14-19, positive >19)	Cr (mg/dL)	Albumin (g/dL)
Aug 2018	7029			
Oct 2018		128		
Feb 2019		<2		
Apr 2019	1094			
Apr 2021	11200	787	2.2	2.2
May 2021		342		
Aug 2021	2700	<4	1.8	4.1

pleural effusions. Urinalysis showed >1000 protein, 24-hr urine protein 11.2 g, Cr 1.6 mg/dL (last known Cr 0.96 in July 2019), and PLA2R Ab 787 RU/mL. Renal biopsy showed immune complex-mediated glomerulopathy with positive PLA2R, consistent with primary MN stage II-III. Glomerular basement membrane deposits were strongly positive for IgG4. Electron microscopy showed numerous subepithelial and occasional intramembranous electron-dense immune-type deposits (see **Figure 1**). She was treated with lisinopril and furosemide with significant clinical improvement. As an outpatient, she was started on rituximab in May 2021. Prior to rituximab, PLA2R Ab was 342 RU/mL, UPCR 8671 mg/g Cr, and Cr 2.2 mg/dL. Three months later, in Aug 2021, her PLA2R Ab had dropped to <4 RU/mL, UPCR 2700 mg/g Cr, and Cr 1.81 mg/dL (see **Table 1**).

Discussion

There is insufficient data on the risk of flares after COVID-19 vaccines in glomerular diseases. Autoimmunity may be triggered by vaccines, including flares of autoimmune glomerulonephritis (GN). MN has been reported following administration of the influenza vaccine. (1-2) Increasingly, both *de novo* and relapse of pre-existing GN's have been reported after COVID-19 messenger RNA (mRNA) vaccines (Moderna mRNA-1273 and Pfizer-BioNTech BNT162b2). These cases are quite rare, and a causal link between COVID-19 vaccines and GN's is not firmly established. Although temporal association does not prove causality, these cases suggest immune-mediated GN flares may be induced by COVID-19 vaccines.

The following *de novo* glomerular diseases have been described following COVID-19 vaccination (3):

IgA nephropathy (IgAN) (4-5)

Anti-neutrophilic cytoplasmic antibody (ANCA)-associated vasculitis (AAV) (6-9)

Minimal change disease (MCD) (3,10)

Primary membranous nephropathy (MN) (11-12)

Anti-glomerular basement membrane (anti-GBM) disease (3)

The following *relapsed* glomerular diseases have been reported following COVID-19 vaccination (3):

IgAN

MCD

Primary MN (13)

Complement-mediated thrombotic microangiopathy

IgG4-related disease (IgG4RD)

Lupus nephritis (LN) class V

Scleroderma renal crisis

Summaries of reported cases of kidney diseases linked to COVID-19 vaccination have been published. (14-15) The number of reported cases likely is an underestimate of true cases. Flares of glomerular diseases have long been reported in association with other vaccines. Examples include MCD after influenza, pneumococcal, smallpox, hepatitis B, and Tdap vaccines; vasculitis after influenza vaccine; and IgAN after recombinant zoster vaccine (Shingrix).(15) Therefore, it is not surprising to find GN's following COVID-19 vaccines.

The pathogenesis of vaccine-associated glomerular diseases is unclear, particularly for the COVID-19 mRNA vaccines, which utilize either a lipid nanoparticle (Pfizer-BioNTech BNT162b2 and Moderna mRNA-1273 vaccines) or an adenoviral vector (AstraZeneca) for mRNA delivery. The mRNA vaccines induce the recipient's cells to synthesize the COVID-19 spike protein via transcription of the injected mRNA. The immune response to vaccination involves both B and T cells. T cell responses, including T follicular helper (Tfh) cells, are stimulated by the lipid nanoparticle-mRNA vaccines. T-cell responses to foreign mRNA provoke swift production of cytokines, which could trigger podocytopathies and augment B-cell production of antibodies and glomerular diseases (e.g., MN).(15)

Different immune mechanisms may play prominent roles in different glomerular diseases following vaccination. It appears that onset of IgAN following COVID-19 vaccination occurs within 1-2 days. In these cases, COVID-19 vaccines may stimulate gut-associated lymphoid tissue (Peyer patches) responsible for IgA1 production, as IgA1 hyperresponsiveness has been observed in IgAN after influenza vaccination.(14) In contrast, onset of MCD, MN, AAV, anti-GBM disease, and IgG4RD following COVID-19 vaccination occurs around 7-14 days later.(14-15) The COVID-19 mRNA vaccines trigger Tfh responses that peak 7 days after immunization. The later presentation of MN, including our case which presented 2 weeks after the second COVID-19 vaccine, may be due to induction of vaccine-associated autoimmunity via antigen-specific and nonspecific mechanisms.(14) The pathophysiologic mechanism behind MN and COVID-19 vaccination requires further study. Furthermore, other confounding factors could also potentially play a role in the risk of MN flare after vaccination. Examples of these confounders include alternative infections (e.g., other upper respiratory viruses or bacterial infections that happen to be present at the time of vaccination), genetic predisposition to autoimmune conditions, or underlying malignancy which may itself cause activation of the immune system.

This case of primary MN flare is only the second reported case of relapse of MN after mRNA COVID-19 vaccination. Only three total cases of MN after COVID-19 vaccination have been reported (two de novo and one relapse).(11-13) Our case adds to the literature supporting this association between MN and COVID-19 vaccination. Most cases of glomerular diseases after COVID-19

vaccination have been reported for MCD and IgAN, but there is a growing number of MN, AAV and other GN's. Interestingly, only one case of LN (class V) has been reported, despite cytokine profiles after vaccination being similar to those from lupus patients (IFN- α , IL-6 and TNF- α).⁽¹⁴⁾ Clinicians should become more aware of the association between vaccination and GN flares, even if patients were in remission for a prolonged time.

Our patient was treated for her primary MN flare with rituximab in a manner similar to non-vaccine-associated MN. Like other reported cases, immunosuppression led to reduced proteinuria and decreased PLA2R Ab significantly. Therefore, close monitoring of patients with MN or other GN's after mRNA COVID-19 vaccination is warranted to allow early treatment to prevent progression to chronic kidney disease or end-stage renal disease.

Conclusions

Our case of primary MN flare after COVID-19 vaccine adds support to a potential association between SARS-CoV-2 antigens and loss of tolerance to the PLA2R antigen. Close follow-up of patients with primary MN and other glomerular diseases after COVID-19 vaccination is warranted. Further studies are needed to determine which COVID-19 vaccines are most likely to cause relapses of GN and to determine mechanisms of immune dysregulation after vaccination.

Declarations

Ethics approval and consent to participate

Ethics approval was not required for this publication, as it is not a clinical trial or study.

Consent for publication

The patient provided informed consent to use her clinical information, pathology slides, laboratory, and radiographic data for publication in this case report.

Availability of data and materials

Data sharing is not applicable to this article as no datasets were generated or analyzed during the current study.

Competing interests

The authors declare that they have no competing interests.

Funding

No sources of funding were used for this publication and had no role in the conceptualization, design, data collection, analysis, decision to publish, or preparation of the manuscript.

Authors' contributions

KVL drafted the initial manuscript and substantively revised it; SBA, ECK, and MP substantively revised the manuscript; MIM provided the photomicrographs and interpretation of the renal pathology. All authors have read and approved the submitted manuscript and agree both to be personally accountable for the authors' own contributions and to ensure that questions related to the accuracy or integrity of any part of the work, even ones in which the authors were not personally involved, are appropriately investigated, resolved, and the resolution documented in the literature.

Acknowledgements

Not applicable.

Abbreviations

AAV - Anti-neutrophilic cytoplasmic antibody (ANCA)-associated vasculitis; Anti-GBM - Anti-glomerular basement membrane; COVID-19 - Coronavirus-19; GN - Glomerulonephritis; IgAN - IgA nephropathy (IgAN); IgG4RD - IgG4 related disease; LN - Lupus nephritis; MCD - Minimal change disease; mRNA - Messenger RNA; MN - Membranous nephropathy; PLA2R - Phospholipase A2 receptor; UPCR - Urine protein/creatinine ratio.

References

1. Kutlucan A, Gonen I, Yildizhan E, et al. Can influenza H1N1 vaccination lead to the membranous glomerulonephritis? *Indian Journal of Pathology & Microbiology* 2012;55(2):239-241.
2. Patel C, Shah HH. Membranous nephropathy and severe acute kidney injury following influenza vaccination. *Saudi Journal of Kidney Diseases and Transplantation* 2015;26(6):1289-1293.
3. Palevsky PM, Radhakrishnan J, Townsend RR. COVID-19: Issues related to acute kidney injury, glomerular disease, and hypertension. *UpToDate* 2022. Last updated: July 20, 2021.
4. Klomjit N, Alexander MP, Fervenza FC, et al. COVID-19 Vaccination and Glomerulonephritis. *Kidney Int Rep* 2021 Dec;6(12):2969-2978.
5. Wu HHL, Kalra PA, Chinnadurai R. New-Onset and Relapsed Kidney Histopathology Following COVID-19 Vaccination: A Systematic Review. *Vaccines (Basel)* 2021 Oct29;9(11):1252.
6. Izzedine H, Bonilla M, Jhaveri KD. Nephrotic syndrome and vasculitis following SARS-CoV-2 Vaccine: True association or circumstantial? *Nephrol Dial Transplant* 2021 Jul 10:215.
7. Anderegg MA, Liu M, Saganas C, et al. De novo vasculitis after mRNA-1273 (Moderna) vaccination. *Kidney Int* 2021; 100:474.
8. Sekar A, Campbell R, Tabbara J, et al. ANCA Glomerulonephritis post Moderna COVID-19 vaccination. *Kidney Int* 2021;100(2):473-474.
9. Shakoor MT, Birkenbach MP, Lynch M. ANCA-associated vasculitis following Pfizer-BioNTech COVID-19 vaccine. *Am J Kidney Dis* 2021;78:611-613.
10. Weijers J, Alvarez C, Hermans MMH. Post-vaccinal minimal change disease. *Kidney Int* 2021;100(2):459-461.
11. Da Y, Goh GH, Khatri P. A case of membranous nephropathy following Pfizer-BioNTech mRNA vaccination against COVID-19. *Kidney Int* 2021 Oct;100(4):938-939.
12. Gueguen L, Loheac C, Saidani N, et al. Membranous nephropathy following anti-COVID-19 mRNA vaccination. *Kidney Int* 2021 Nov;100(5):1140-1141.
13. Aydın MF, Yıldız A, Oruç A, et al. Relapse of primary membranous nephropathy after inactivated SARS-CoV-2 virus vaccination. *Kidney Int* 2021 Aug;100(2):464-465.
14. Li NL, Coates PT, Rovin BH. COVID-9 vaccination followed by activation of glomerular diseases: does association equal causation? *Kidney Int* 2021;100:959-965.

15. Bomback AS, Kudose S, D'Agati VD. De Novo and Relapsing Glomerular Diseases After COVID-19 Vaccination: What Do We Know So Far? *Am J Kidney Dis* 2021; 78:477.