

Acute Peritonitis: A Rare Complication Revealing Intestinal Tuberculosis

Sabbah.M^{1,*}, Trad.D¹, Jemmali.C¹, Jouini R¹, Elloumi H¹, Bibani.N¹,
Ouakaa.A¹, Gargouri.D¹

¹Gastroenterology Department, Habib Thameur Hospital Tunis

Abstract

Intestinal tuberculosis diagnosis is often difficult because of non-specific symptoms, miming many other conditions such as malignancy, infectious disease, and inflammatory bowel disease.

Free intestinal perforation is an uncommon but life-threatening complication of intestinal tuberculosis, associated with high morbidity and mortality.

Corresponding author: Sabbah.M, Gastroenterology Department, Habib Thameur Hospital Tunis, Tunisia, Email: sabbah_meriam@yahoo.fr

Keywords: Intestinal tuberculosis diagnosis, infectious disease, inflammatory bowel disease

Citation: Sabbah.M , Trad.D , Jemmali.C , Jouini R, Elloumi H et al. (2019) Acute Peritonitis: A Rare Complication Revealing Intestinal Tuberculosis. Journal of Spleen and Liver Research - 1(3):15-17. <https://doi.org/10.14302/issn.2578-2371.jslr-19-3028>

Received: Sep 13, 2019

Accepted: Sep 25, 2019

Published: Sep 30, 2019

Editor: Sunder Goyal, Department of Minimal Invasive and General Surgery, Kalpana Chawla Government Medical College, Haryana, India.

Introduction

Intestinal tuberculosis diagnosis is often difficult because of non-specific symptoms, miming many other conditions such as malignancy, infectious disease, and inflammatory bowel disease.

Free intestinal perforation is an uncommon but life-threatening complication of intestinal tuberculosis, associated with high morbidity and mortality.

Case Report

A 34-year-old alcohol-smoking man presented to the emergency department with acute epigastric pain, associated with fever.

On examination, his abdomen was diffusely tender with board-like rigidity, while digital rectal examination was painful.

Laboratory investigations revealed inflammatory

reaction (raised white blood cell, C-Reactive protein 140mg/l), associated with hypochromic anemia.

Viral hepatitis serologies and HIV were negative.

Abdomen and chest radiography showed pneumoperitoneum (Fig-1).

On emergency laparoscopy, there was purulent generalized peritonitis, without evidence of digestive perforation. Laparotomy was made, revealing two distinct sites of ileum perforations 15cm from the ileocecal valve. There were strictures in the small intestine, with multiple mesenteric lymphadenitis. Ileocaecal resection and ileostomy were performed.

Postoperatively the Patient had Uneventful Recovery

The histopathologic examination of the resected bowel specimen showed caseating granulomatous inflammation (Fig-2), consistent with intestinal small

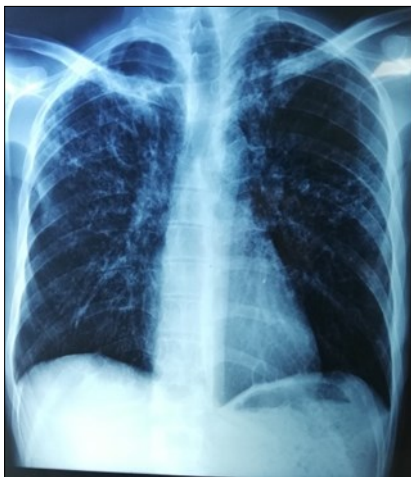

Figure 1. Pneumoperitoneum on chest X Ray

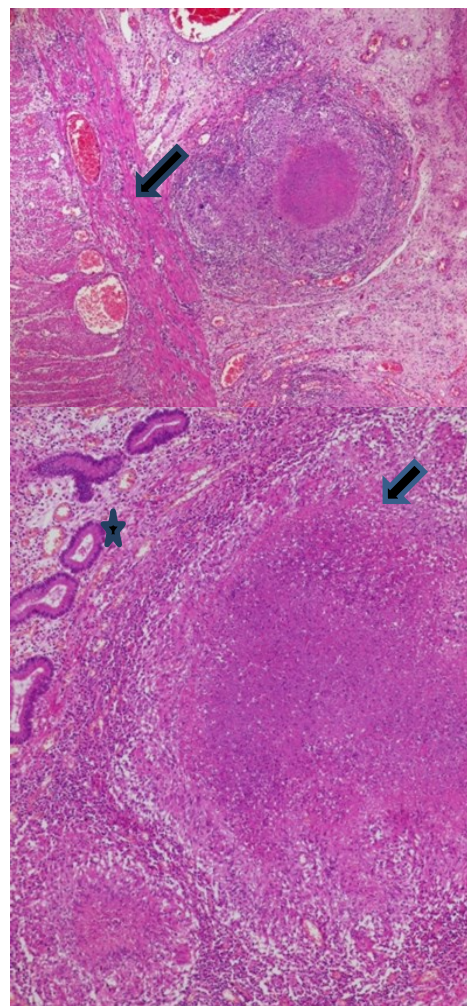


Figure 2. Epithelioid granuloma and giant cells (Arrow) with caseous necrosis (Star)

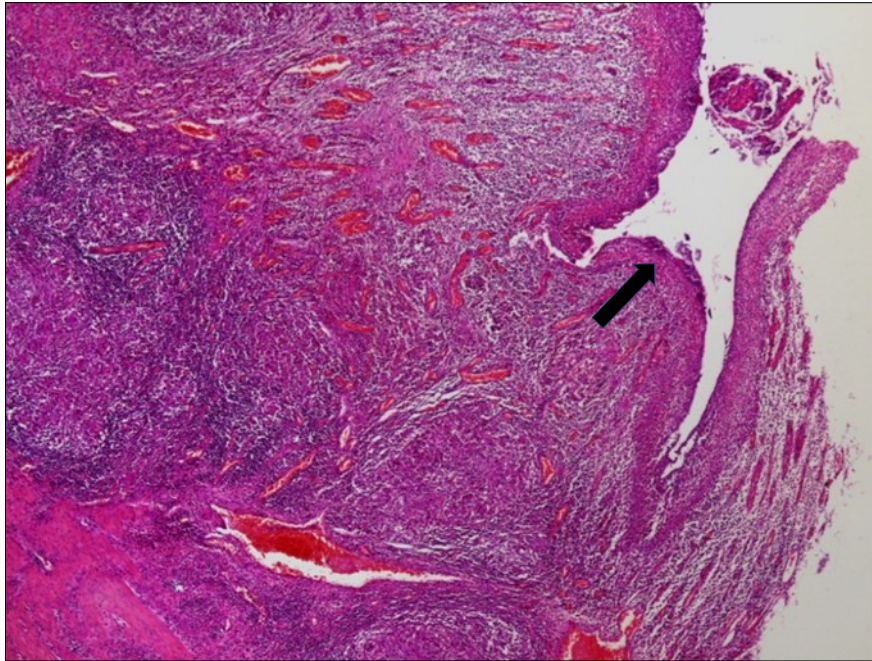


Figure 3. Signs of acute peritonitis in the intestinal mucosa

bowel tuberculosis complicated with peritonitis and perforation (Fig-3).

The patient was started on anti-tuberculosis treatment.

Discussion

Free perforations occur in 1 to 15% of patients with intestinal tuberculosis and it is associated with mortality of about 30%. Factors linked with increased mortality were age, comorbidities, multiple perforations and delayed surgery.¹

The most common site of perforation is the terminal ileum -with is our case- while the majority (90%) of perforations are solitary.²

As surgical modality, the resection of the affected area and anastomosis may be the treatment of choice rather than primary closure.³

Conclusion

Perforation is a serious complication of intestinal tuberculosis. Only early surgical treatment can improve survival.

References

1. Lee MJ, Cresswell FV, John L, et al. Diagnosis and treatment strategies of tuberculous intestinal perforations. *Eur J Gastroenterol Hepatol.*

2012;24:594Y599

2. Kakar A, Aranya RC, Nair SK. Acute perforation of small intestine due to tuberculosis. *Aust NZ J Surg* 1983;53:381-383.
3. Ara C, Sogutlu G, Yildiz R. Spontaneous small bowel perforations due to intestinal tuberculosis should not be repaired by simple closure. *J Gastrointest Surg* 2005;9:514-517.